Gong *et al.*
Clinical Diabetes and Endocrinology (2024) 10:37
https://doi.org/10.1186/s40842-024-00198-1

Clinical Diabetes and Endocrinology

CASE REPORT

Open Access

Metanephrine mirage: distinguishing the phaeocopies, a case report and literature review

Joanna Y. Gong[1*], Debbie Gordon[1,2], Sylvia Ye[1], Bill Fleming[3], Jason Tan[3], Toby Hulf[3], Maryam Shamassi[4], Lisa M. Orme[5,6,7], Nezor Houli[8], Emma Boehm[9], Christopher J. Yates[1,6] and Dev A. Kevat[1,10]

Abstract

Background We present one of only seven reported cases of a catecholamine-secreting adrenal neuroblastoma in an adult. The case is used as a platform to discuss key biochemical, genomic and imaging considerations that are central to the successful, targeted management of catecholamine-secreting adrenal tumours.

Case presentation A 63-year-old male was urgently reviewed at a tertiary hospital endocrinology outpatient clinic for a 12 cm right-sided adrenal incidentaloma. Plasma normetanephrine and 3-methoxytyramine levels were approximately 10 times the upper limit of normal at 9272 pmol/L (< 900) and 1023 pmol/L (< 110), respectively.

The adrenal mass appeared to be inseparable from the liver on imaging, and thus was suspected to be an invasive malignant phaeochromocytoma. FDG positron emission tomography (PET)/CT demonstrated moderate to intense metabolic activity within the right adrenal mass. [68 Ga]Ga-DOTATATE (Ga-TATE) PET-CT demonstrated patchy, heterogenous somatostatin receptor (SSTR) expression in the adrenal lesion, at most Krenning 3 (intensity above liver).

The patient underwent a right adrenalectomy and segment 6/7 liver resection. Histopathology revealed a 130 mm diameter neuroblastoma of the differentiating subtype with a low Mitosis-Karyorrhexis Index. There was lymphovascular invasion and tumour focally present at the resection margin, but no tumour in one periadrenal lymph node, and no tumour invasion in the adherent liver. Immunohistochemistry revealed ALK positivity (+ 3) and wild type ATRX.

At nine months following adrenalectomy, the plasma normetanephrine level has reduced to 991 pmol/L (< 900). Postoperative GaTate PET/CT shows no definite abnormal SSTR-expressing lesions in the surgical bed or elsewhere. The patient has completed adjuvant radiotherapy and is a candidate for ALK-targeted therapy if required for recurrence in the future.

Conclusions Neuroblastomas may be misdiagnosed as phaeochromocytomas given the ability to secrete catecholamines and similarities in radiological appearance. Differentiating neuroblastomas from phaeochromocytomas and paragangliomas (PPGL) is critical, but clinically difficult. Genomics are central for management; diagnosing ALK-positive neuroblastoma triggers consideration of ALK-targeted therapy, which is not relevant for PPGL. A critical eye is required for the accurate diagnosis and management of malignant adrenal incidentalomas.

Keywords Neuroblastoma, Adrenal, Metanephrine, Incidentaloma, Phaeochromocytoma, Malignancy, Catecholamine

*Correspondence:
Joanna Y. Gong
Joanna.Gong@baker.edu.au
Full list of author information is available at the end of the article

© The Author(s) 2024. **Open Access** This article is licensed under a Creative Commons Attribution 4.0 International License, which permits use, sharing, adaptation, distribution and reproduction in any medium or format, as long as you give appropriate credit to the original author(s) and the source, provide a link to the Creative Commons licence, and indicate if changes were made. The images or other third party material in this article are included in the article's Creative Commons licence, unless indicated otherwise in a credit line to the material. If material is not included in the article's Creative Commons licence and your intended use is not permitted by statutory regulation or exceeds the permitted use, you will need to obtain permission directly from the copyright holder. To view a copy of this licence, visit http://creativecommons.org/licenses/by/4.0/. The Creative Commons Public Domain Dedication waiver (http://creativecommons.org/publicdomain/zero/1.0/) applies to the data made available in this article, unless otherwise stated in a credit line to the data.

Background

Neuroblastomas are undifferentiated tumours originating from sympathetic ganglia, and may be mistaken for a phaeochromocytoma or paraganglioma (PPGL). We present the case of a catecholamine-secreting adrenal neuroblastoma in an adult, one of only seven such reported cases [1–7].

Adrenal incidentalomas are found in 2% of the population [8]. It was previously thought that up to 10–15% of adrenal incidentalomas were associated with hormone excess [8, 9]. A recent study, however, of incidentalomas greater than 1 cm in diameter found 28.2% of adrenal incidentalomas were functional [10]. Around 2% of adrenal incidentalomas are adrenal cortical cancers, and other less common tumours may present a complex and confounding clinical picture [8].

Neuroblastoma is a very rare cause of an adrenal incidentaloma in adults. While also rare, PPGLs are more likely to occur in adults and originate from the adrenal chromaffin cells and autonomic ganglia respectively. We will describe the genomic features of neuroblastomas, how this differs from PPGLs, and key genomic and imaging considerations for successful therapy.

Case presentation

A 63-year-old male was urgently reviewed at a tertiary hospital endocrinology outpatient clinic for a 12 cm right-sided adrenal incidentaloma. This was identified on a chest computed tomography (CT) scan performed to investigate weight loss. He was a heavy smoker (59 pack-year history), with chronic obstructive pulmonary disease, schizophrenia and depression. His mental health was stable, and medications included clozapine and venlafaxine.

The patient had asymptomatic hypertension with a systolic blood pressure of 134 – 163 mmHg. He reported no palpitations or headaches. Plasma normetanephrine and 3-methoxytyramine (3-MT) levels were approximately 10 times the upper limit of normal at 9272 pmol/L (< 900) and 1023 pmol/L (< 110), respectively. Plasma metanephrine levels were unremarkable. A 24-h urine collection was concordant, with an elevated normetanephrine:creatinine ratio of 2.6 mmol/mol (< 0.25), 3-MT:creatinine ratio of 2168micromol/mol (< 197), and metanephrine:creatinine ratio of 0.17 mmol/mol (< 0.10). The aldosterone:renin ratio, 1 mg dexamethasone suppression test, serum sodium, serum potassium and DHEA-S levels were unremarkable (Table 1).

A dedicated contrast adrenal CT scan confirmed a right adrenal mass measuring 12.2 cm × 9.7 cm × 10.7 cm. There was heterogeneous post-contrast enhancement with enhancing solid areas and non-enhancing necrotic and cystic areas. It was not consistent with a lipid-rich adrenal adenoma, with low absolute and relative contrast washout estimated at 39% and 28%, respectively. The adrenal mass was thought to be inseparable from the liver on imaging (Fig. 1), and thus suspected to be an invasive malignant phaeochromocytoma. FDG positron emission tomography (PET)/CT demonstrated moderate to intense metabolic activity within the right adrenal mass and an intensely-avid right inguinal node, raising concern for metastasis. On [^{68}Ga]Ga-DOTATATE (Ga-TATE)

Table 1 Biochemistry prior to and following adrenalectomy

	Pre-operative	Post-operative	Reference range
Plasma			
Normetanephrine	9272 pmol/L	991 pmol/L	< 900 pmol/L
Metanephrine	368 pmol/L	–	< 500 pmol/L
3-methoxytyramine	1023 pmol/L	134 pmol/L	< 110 pmol/L
24-h urine			
Normetanephrine:Cr	2.6 mmol/mol	0.26 mmol/mol	< 0.25 mmol/mol
Metanephrine:Cr	0.17 mmol/mol	0.05 mmol/mol	< 0.10 mmol/mol
3-methoxytyramine:Cr	2168 µmol/mol	–	< 197 µmol/mol
Other functional testing			
1 mg DST	61 nmol/L	–	< 50 nmol/L
Salivary cortisol	2.3 nmol/L	–	3 – 35 nmol/L
24-h urine cortisol	161 nmol/L (volume 2180 mL)	–	< 280 nmol/L
Aldosterone:renin ratio	34	–	< 71
Sodium	138 mmol/L	–	135 – 145 mmol/L
Potassium	4.4 mmol/L	–	3.5 – 5.2 mmol/L
DHEA-S level	0.3 µmol/L	–	3.0 – 10.5 µmol/L

Cr Creatinine, *DST* Dexamethasone suppression test

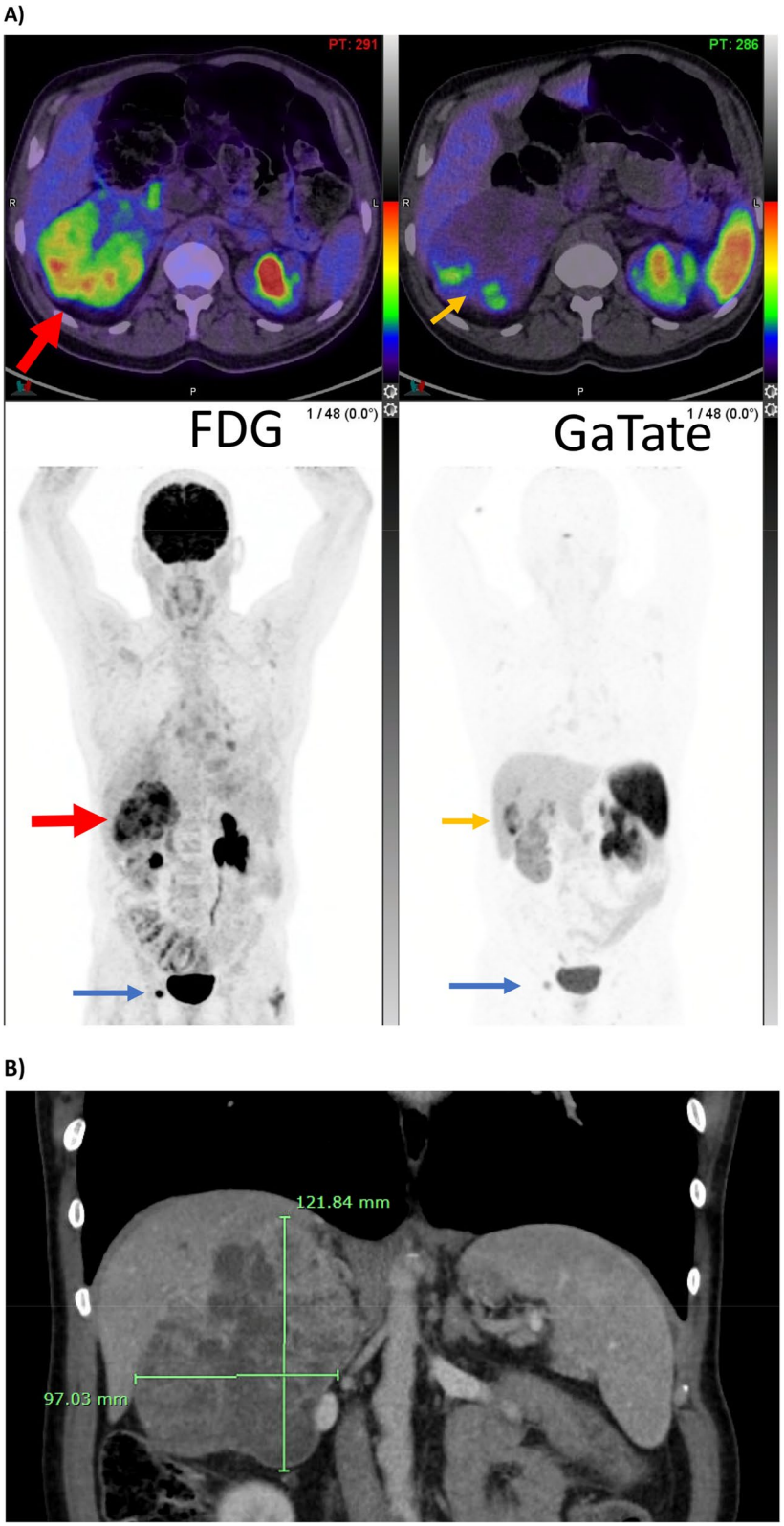

Fig. 1 **A** FDG (left panel) and GaTate (right panel) maximum intensity projections (bottom) and upper abdominal axial slice demonstrating a moderate to intensely FDG-avid right adrenal lesion (red arrows) with corresponding patchy, peripheral somatostatin receptor expression on GaTate (orange arrows), as well as a single intensely FDG-avid right inguinal lymph node (blue arrows). **B** Contrast adrenal CT demonstrating measurements of the large right adrenal mass (rulers)

PET-CT, the adrenal lesion demonstrated patchy, heterogenous somatostatin receptor (SSTR) expression, at most Krenning 3 (intensity above liver). An echocardiogram was unremarkable.

The patient was commenced on alpha-blockade with phenoxybenzamine. It was initiated at 10 mg twice daily, then uptitrated to 30 mg twice daily to achieve a systolic blood pressure of 100-110 mmHg.

Given the patient's comorbidities and high mortality risk with attempted surgery, a multidisciplinary team discussion recommended an excisional inguinal node biopsy to exclude metastases. The inguinal node biopsy showed reactive tissue only.

Given suspected hepatic invasion, the patient then proceeded to a right adrenalectomy and segment 6/7 liver resection (Fig. 2). Histopathology revealed a 130 mm diameter neuroblastoma of the differentiating subtype with a low Mitosis-Karyorrhexis Index. There was lymphovascular invasion and tumour focally present at the resection margin, but no tumour in one periadrenal lymph node and no tumour invasion in the adherent liver (Fig. 3). Immunohistochemistry revealed ALK positivity (+3) and wild type ATRX.

Post-operatively, phenoxybenzamine was ceased, and he recovered well after a brief period of inotropic support. At nine months following adrenalectomy, the plasma normetanephrine level has reduced to 991 pmol/L (< 900), with persistent minor elevation attributed to venlafaxine. The 24-h urine normetanephrine:creatinine ratio is 0.26 mmol/mol (< 0.25), and the metanephrine:creatinine ratio is 0.05 mmol/mol (< 0.10). Post-operative GaTate PET/CT shows no definite abnormal SSTR-expressing lesions in the surgical bed or elsewhere. The patient has completed adjuvant radiotherapy and is a candidate for ALK-targeted therapy if required for recurrent or metastatic disease in the future.

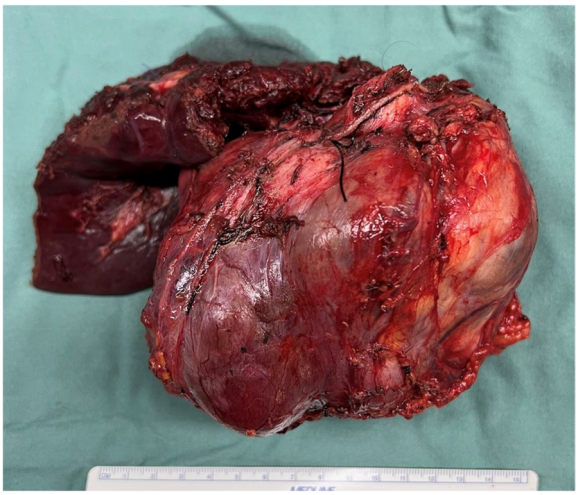

Fig. 2 Right adrenal mass, with partial liver resection

Discussion and conclusions

Neuroblastic tumours arise from sympathetic ganglion cells, comprising of neuroblastomas (immature, malignant), ganglioneuroblastomas (intermediate), and ganglioneuromas (mature). Neuroblastomas usually affect children, being extremely rare in adults. The most common sites for adult-onset neuroblastoma are adrenal, abdominal paraspinal, and mediastinal [11].

Clinical presentation of adult neuroblastoma is variable; the most common symptoms are abdominal pain and sequelae from impingement on neighbouring viscera. However, neuroblastoma may also present as adrenal incidentalomas and may secrete catecholamines, aldosterone or adrenocorticotropic hormone (ACTH) [1]. Medications may also increase plasma metanephrine levels [12], including venlafaxine taken by our patient, which has been reported to increase normetanephrine to more than four-fold the upper limit of normal [13–15]. Isolated elevations in metanephrine or normetaphrine levels at least three-fold the upper limit of normal, however, are unlikely to be false positives. This should prompt further investigations to detect a PPGL or neuroblastoma [16].

Neuroblastomas may be misdiagnosed as phaeochromocytomas given the ability to secrete catecholamines. They may also have similar radiological features, including heterogeneous contrast uptake on CT and poorly-defined margins [17]. They are usually identified in the retroperitoneum or pelvis [17]. To date, all reported cases of catecholamine-secreting adrenal adult neuroblastomas have been very large, ranging in size from 8 cm to 24.1 cm. The resected neuroblastoma described in this case was 15 cm in diameter (Fig. 2).

Interestingly, the neuroblastoma described here had biochemical and imaging profiles suggestive of a pseudohypoxic subtype phaeochromocytoma; there were elevated normetanephrine and 3-MT levels but normal metanephrine levels, together with both FDG and SSTR-avidity on nuclear imaging.

Surgery is the primary treatment for localised disease, with adjuvant chemotherapy and radiotherapy offered depending on stage, histology, grade and genetic prognostic factors [1]. A high proportion of adult patients – up to 75% of cases in one series [11] – present with metastatic disease. Thus, there is an imperative for genomic testing in these patients to evaluate for targeted systemic treatment options.

The genomic landscape of adult neuroblastoma differs from paediatric tumours. For example, a published cohort analysis of 26 adult neuroblastoma patients who had varying methods of genomic testing describes 42%

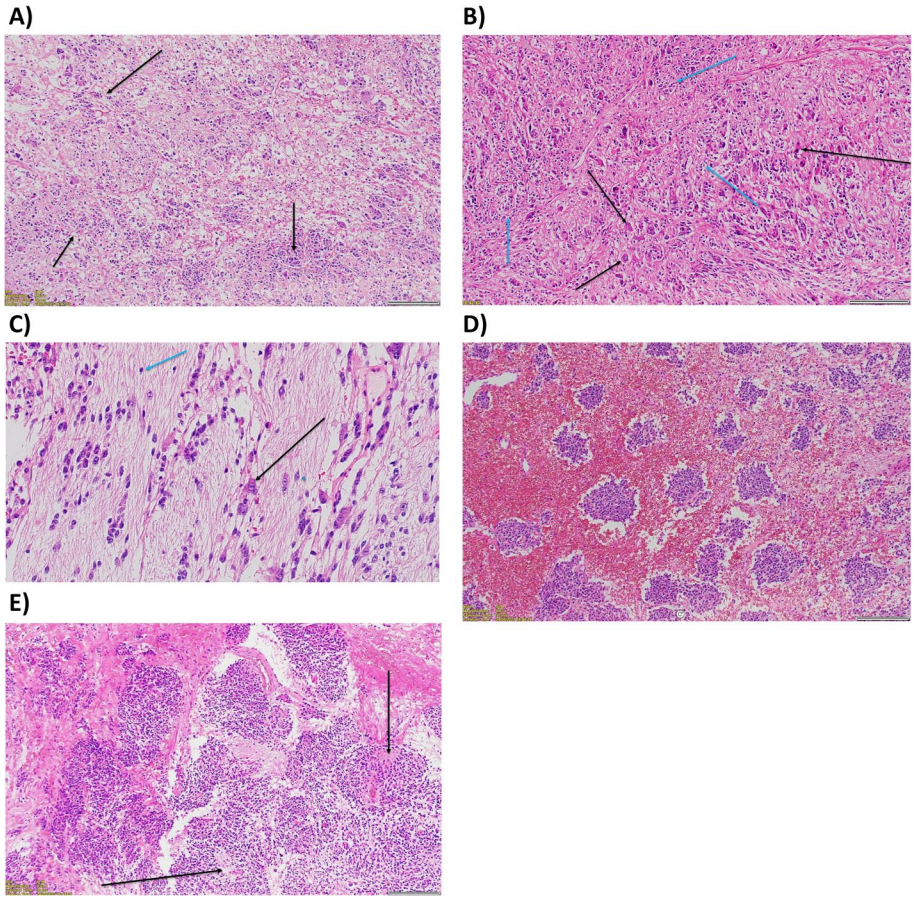

Fig. 3 Resected neuroblastoma histology, demonstrating **A** Low-power view of the tumour with nests of small blue primitive-appearing cells floating within an oedematous and fibrillary background, **B** Medium power view demonstrating a variety of tumour cells ranging from small- and primitive-appearing (neuroblasts, yellow arrow) to larger cells with moderate amounts of eosinophilic cytoplasm and large nuclei (ganglion cells, black arrow) against a neurofibrillary background, **C** Higher power view demonstrating morphology of tumour cells in different stages of maturation from neuroblasts (blue arrow) to ganglion cells (black arrow), **D** Nests of undifferentiated neuroblasts against a haemorrhagic background, and **E** Pseudo-Rosette formation: arrangement of tumour cells around a central area filled with neurofibrillary processes

with activating ALK mutations and 58% with ATRX loss-of-function mutations [11]. Both of these mutations occur less frequently in paediatric tumours, which are more commonly driven by MYCN-amplification [11, 18]. The high frequency of ALK-mutations in adult neuroblastoma offers the potential for targeted therapy with ALK-inhibitors for patients with metastases or recurrent disease, as is available for our patient.

There may be additional mutations in adults as yet unrecognised due to rarity of the condition and limited available tumour genomic data. Further research is required to investigate genomic differences between adult and paediatric cases, and understand why adult neuroblastomas carry a worse prognosis than paediatric neuroblastomas [11].

Including this case, only seven cases of catecholamine-secreting adrenal neuroblastoma in adults have been described in the literature [1–7]. Prior to surgical resection and histological review, the differentials for this case included pseudohypoxic subtype phaeochromocytoma, and composite phaeochromocytoma. There are no established clinical or radiological criteria to distinguish catecholamine-secreting neuroblastoma from PPGL. Histology was critical for this case given adjuvant therapy for neuroblastoma differs from PPGL, with the former treated with radiotherapy. Surveillance and genetic testing also differ between the two pathologies. Diagnosing ALK-positive neuroblastoma triggers consideration of ALK-targeted therapy, which is not relevant for PPGL. A critical eye is required for the accurate diagnosis and management of malignant adrenal incidentalomas.

Abbreviations

3-MT	3-Methoxytyramine
ACTH	Adrenocorticotropic hormone
ALK	Anaplastic lymphoma kinase
ATRX	Alpha-thalassemia mental retardation X-linked

CT	Computed tomography
Ga-TATE	[^{68} Ga]Ga-DOTATATE
MYCN	V-myc myelocytomatosis viral-related oncogene, neuroblastoma derived
PPGL	Phaeochromocytoma and paraganglioma
PET	Positron emission tomography
SSTR	Somatostatin receptor

Acknowledgements
Thank you to Jesenka Jefic for facilitating essential ALK and ATRX testing for this gentleman.

Authors' contributions
JYG drafted the initial manuscript. All authors contributed to the multidisciplinary clinical care of the patient and reviewed the manuscript.

Authors' information
This was a difficult case requiring multidisciplinary care. DAK (Acting Head of Department), CJY (Co-director of Research, Department of Endocrinology and Diabetes) and DG are endocrinologists. JYG and SY are endocrinology trainees. BF (Head of Department) and JT are endocrine surgeons. TH is an endocrine surgery fellow. MS (Head of Department) is an anatomical pathologist. EB is a dual-trained nuclear medicine physician and endocrinologist with expertise in neuroendocrine tumours. LMO is a paediatric oncologist with expertise in neuroblastoma management. NH is the general surgeon who guided the liver resection.

Funding
There was no funding for this study.

Availability of data and materials
The data for this case report are available upon request from the corresponding author, given that ethics clearance has been obtained.

Declarations

Ethics approval and consent to participate
Not applicable.

Consent for publication
The person described provided informed consent for publication of the case.

Competing interests
The authors declare that they have no competing interests.

Author details
[1]Department of Endocrinology and Diabetes, Western Health, 176 Furlong Rd, St Albans, VIC 3021, Australia. [2]Department of Endocrinology and Diabetes, Eastern Health, 5 Arnold St, Box Hill, VIC 3128, Australia. [3]Department of Endocrine Surgery, Western Health, 176 Furlong Rd, St Albans, VIC 3021, Australia. [4]Department of Anatomical Pathology, Dorevitch Pathology, Western Health, Cnr Gordon St & Ballarat Rd, Footscray, VIC 3011, Australia. [5]The Children's Cancer Centre, The Royal Children's Hospital, 50 Flemington Rd, Parkville, VIC 3052, Australia. [6]Department of Medicine, University of Melbourne, 300 Grattan St, Parkville, VIC 3052, Australia. [7]Department of Medical Oncology, Peter MacCallum Cancer Centre, 305 Grattan St, Melbourne, VIC 3000, Australia. [8]Department of General Surgery, Western Health, Cnr Gordon St & Ballarat Rd, Footscray, VIC 3011, Australia. [9]Department of Nuclear Medicine, Peter MacCallum Cancer Centre, 305 Grattan St, Melbourne, VIC 3000, Australia. [10]Department of Endocrinology and Diabetes, Monash Health, 246 Clayton Rd, Clayton, VIC 3168, Australia.

Received: 5 April 2024 Accepted: 19 July 2024
Published online: 16 November 2024

References

1. Telecan T, Andras I, Bungardean MR, et al. Adrenal gland primary neuroblastoma in an adult patient: A case report and literature review. Medicina. 2023;59(1):33.
2. Suzuki H, Honzumi M, Funada M, et al. Metachronous bilateral adrenal neuroblastoma. Cancer. 1985;56:1490–2.
3. Genc H, Haciyanli M, Haciyanli SG, et al. An adult adrenal neuroblastoma: A case report. Acta Chir Belg. 2005;105(6):673–6.
4. Schalk E, Mohren M, Koenigsmann M, et al. Metastatic adrenal neuroblastoma in an adult. Onkologie. 2005;28(6–7):353–5.
5. Manjunath S, Mouli S, Singh KR, et al. Neuroblastoma in late adolescence: Case report and review of literature. World J Endoc Surg. 2018;10(3):157–62.
6. McCarthy LC, Chastain K, Flatt TG, et al. Neuroblastoma in adolescents and children older than 10 years: Unusual clinicopathologic and biologic features. J Pediatr Hematol Oncol. 2019;41:586–95.
7. Guzman Gómez GE, Urbano MA, Martínez V. Adrenal neuroblastoma producing catecholamines diagnosed in adults: Case report. Case Rep Oncol. 2022;15:682–6.
8. Sherlock M, Scarsbrook A, Abbas A, et al. Adrenal incidentaloma. Endocr Rev. 2020;41(6):775–820.
9. Nieman LK. Approach to the patient with an adrenal incidentaloma. J Clin Endocrinol Metab. 2010;95(9):4106–13.
10. Yilmaz N, Avsar E, Tazegul G, et al. Clinical characteristics and follow-up results of adrenal incidentaloma. Exp Clin Endocrinol Diabetes. 2021;129(05):349–56.
11. Suzuki M, Kushner BH, Kramer K, et al. Treatment and outcome of adult-onset neuroblastoma. Int J Cancer. 2018;143(5):1249–58.
12. Eisenhofer G, Pamporaki C, Lenders JW. Biochemical assessment of pheochromocytoma and paraganglioma. Endocr Rev. 2023;44(5):862–909.
13. Neary NM, King KS, Pacak K. Drugs and pheochromocytoma—don't be fooled by every elevated metanephrine. N Engl J Med. 2011;364(23):2268–70.
14. Mañas-Martínez AB, Aragoneses-Calvo A, Matei A, et al. Venlafaxine drug interaction in the diagnosis of pheochromocytoma. Endocrinologia y Nutricion: Organo de la Sociedad Espanola de Endocrinologia y Nutricion. 2016;63(10):569–70.
15. Remde H, Pamporaki C, Quinkler M, et al. Improved diagnostic accuracy of clonidine suppression testing using an age-related cutoff for plasma normetanephrine. Hypertension. 2022;79(6):1257–64.
16. Lenders JW, Duh Q-Y, Eisenhofer G, et al. Pheochromocytoma and paraganglioma: an endocrine society clinical practice guideline. J Clin Endocrinol Metab. 2014;99(6):1915–42.
17. Tateishi U, Hasegawa T, Makimoto A, et al. Adult neuroblastoma: Radiologic and clinicopathologic features. J Comput Assist Tomogr. 2003;27(3):321–6.
18. Sarnacki S, Pio L. Neuroblastoma: Clinical and surgical management. Cham (Switzerland): Springer Nature; 2020.

Publisher's Note

Springer Nature remains neutral with regard to jurisdictional claims in published maps and institutional affiliations.